

Ultrasound assessment of soft tissue augmentation around implants in the aesthetic zone using a connective tissue graft and xenogeneic collagen matrix – 1-year randomised follow-up[☆]

Monika Puzio^b, Artur Błaszczyszyn^a, Jakub Hadzik^{a,*}, Marzena Dominiak^a

^a Department of Dental Surgery, Silesian Piast Medical University of Wrocław, Poland

^b University Polyclinic of Dentistry of Wrocław, Poland

ARTICLE INFO

Article history:

Received 22 September 2017

Received in revised form 25 October 2017

Accepted 1 November 2017

Keywords:

Thickness keratinized gingiva

Connective tissue graft

Mucograft[®]

Ultrasound measurements

ABSTRACT

Purpose: A comparative, ultrasound evaluation of the thickness of keratinized mucosa (TKT) around implants one year after gingival augmentation (GA) by means of a connective tissue graft (CTG) and the xenogeneic collagen matrix (CMX).

Materials and methods: A total of 75 bone level tapered implants (Conelog[®] Camlog) were inserted in 57 patients in the aesthetic area of both jaws. The patients were divided into 3 groups: control group I- without GA; group II- GA 3 months before implantation, and group III- GA 3 months after implantation. Groups II and III were divided into two subgroups depends on type of material used for GA: (a) CMX (Mucograft[®], Geistlich Pharma AG) and (b) CTG. The patients underwent a clinical and ultrasound examination before, then after 3 and 12 months following GA respectively to evaluate TKT at two points using ultrasound equipment (Piro[®], Echoson). Point 1 was considered to be in the middle of the line connecting the cemento-enamel junction (CEJ) to the adjacent teeth, and point 2 on the mucogingival junction (MGJ).

Results: Three months after GA, the highest increase in gingival thickness was noted in group IIIb (point 1 – 0.95 mm, 2 – 1.01 mm). However, 12 months after GA the highest gingival thickness was observed in group IIb (point 1 – 1.76 mm, 2 – 1.36 mm) and next IIIb (point 1 – 1.52 mm, 2 – 1.15 mm).

Conclusions: Both CTG and Geistlich Mucograft[®] increased TKT, but higher values were noted using CTG augmentation before implantation. An ultrasonic device can be used as a non-invasive, reliable, and reproducible method for evaluating TKT.

© 2017 Elsevier GmbH. All rights reserved.

1. Introduction

Anterior implant aesthetics still pose an enormous challenge. To achieve positive aesthetic and therapeutic results it requires taking into account many factors, such as patient and site related factors, implants and technique related factors e.g. tissue biotype and presence of keratinized gingiva around the implants. Berglundh and Lindhe (1996) stated that cut off point for gingival biotype is 2 mm. The biotype below 2 mm is referred to as thin, the biotype equal or above 2 mm is referred as thick. Long-term observations show that the predictability of implant survival in patients with a

thin biotype is low (Kao and Pasquinelli, 2002; Kao et al., 2008). The limited thickness and width of keratinized gingiva (KG) is a major factor that increases the occurrence of gingival recessions around implants, just as it also increases the risk of inflammation (Schlegel et al., 1994). Linkevicius et al. claim that keratinized gingiva thickness above 2 mm is an important factor maintaining a stable marginal bone level around the implant and prevents implant loss after loading (Linkevicius et al., 2009; Linkevicius and Puisys, 2015). Therefore, the keratinized gingiva around implants should be thicker than around teeth so as to prevent recession and secondary inflammation occurring after many years of implant use (Zuhr and Hürzeler, 2012). Moreover, a thick phenotype has shown to have a better emergence profile for implant-supported crowns (Jung et al., 2007).

To increase the thickness of keratinized gingiva different soft tissue augmentation procedures are performed. Soft tissue augmentation methods include pedicle flaps (Scharf and Tarnow, 1992)

[☆] This paper belongs to the special issue Dentistry 2017.

* Corresponding author at: Oral Surgery Department Medical University of Wrocław, Krakowska 26 St., 50-425 Wrocław, Poland.

E-mail address: jakub.hadzik@umed.wroc.pl (J. Hadzik).

and autogenous tissue grafts (Langer and Calagna, 1980; Hürzeler and Weng, 1999). Numerous techniques are used to harvest a free connective tissue graft (CTG). These differ from one another in terms of the number and types of incisions made (Langer and Calagna, 1980; Hürzeler and Weng, 1999). However, connective tissue graft harvesting carries an additional burden for the patient, mainly in the form of a second operating field and the pain this entails. An alternative approach involves using connective tissue substitutes of allo- and xenogenous origin, as well as gelatine, fibrin or synthetic matrices (Moharamzadeh et al., 2008; Dominiak et al., 2012a,b). Moreover, recently, xenografts collagen matrix (CMX) have been successfully used as an effective grafting material in studies examining ways of increasing the thickness of periimplant keratinized tissue (Schallhorn et al., 2015; Froum et al., 2015).

Nowadays, augmentation of soft tissue using different methods is a predictable procedure, but the standardized measure of keratinized gingiva thickness is still the major challenge (Thoma et al., 2009; Studer et al., 2000). An easy, but at the same time invasive method involves assessing thickness with a periodontal probe (Batista et al., 2001; Rasperini et al., 2015; Mohan et al., 2011) or via punching with an endodontic tool (TGP – *transgingival probing*, Bs – *bone sounding*) (Studer et al., 1997). However, those methods are limited by a measurement error resulting from reading the measured values on the millimetre scale or prosthetic thickness gauge. Recently, non-invasive methods such as computerized tomography (CT) (Windisch et al., 2007; Schneider et al., 2011) and ultrasound devices have been developed for the purpose of measuring soft tissue thickness (Uchida et al., 1989; Muller et al., 1999). The latter method causes no radiation and satisfactory reproducibility of examination.

The objective of the study has been to provide a comparative, ultrasound assessment of the thickness of keratinized gingiva around implants over a one-year observation period following

gingival augmentation in the aesthetic area using CTG or CMX. Moreover, the aim has been to establish an algorithm for the procedure using different materials and different time (before or after) for soft tissue augmentation around implants.

2. Materials and methods

2.1. Patient selection

The treatment was performed on generally healthy, adult patients at the Department of Oral Surgery, Wrocław Medical University in Poland. The study was carried out between May 2012 and September 2014. To be included in the study, patients had to have missing single or double teeth in the anterior area of their upper or lower jaw with a proper inter arch relationship (incisors, canines and first premolar) with a ridge width (bucco-lingual) greater than 5 mm at its narrowest point and a minimum height of keratinized gingiva of 2 mm measured buccally with a periodontal probe.

Exclusion criteria included:

- general contraindications for implant surgery;
- irradiation in the head and neck area;
- treatment or under treatment with intravenous aminobisphosphonates;
- immunosuppression or immunodepression drugs;
- untreated periodontitis;
- poor oral hygiene (plaque score API 20%, bleeding score 10%) and poor motivation;
- uncontrolled diabetes;
- pregnancy or nursing;
- metabolic disease and drugs affecting bone remodelling;
- bruxism or clenching;

Table 1
Comparison of demographic data between groups at baseline.

	Group I	Group IIa	Group IIb	Group IIIa	Group IIIb	Test
Sex						
Female	9 (60.0%)	12 (80.0%)	11 (73.3%)	10 (66.7%)	6 (40.0%)	$p = 0.189^a$
Male	6 (40.0%)	3 (20.0%)	4 (26.7%)	5 (33.3%)	9 (60.0%)	
Age [years]						
$M \pm SD$	43.3 \pm 17.4	43.7 \pm 13.7	38.1 \pm 16.5	42.1 \pm 15.3	41.1 \pm 11.9	$p = 0.858^b$
$Me (Q_1; Q_3)$	37 (26; 62)	44 (38; 52)	36 (22; 56)	43 (29; 59)	43 (30; 48)	
$Min - Max$	20–65	16–63	16–63	19–64	19–59	
Smokers	0 (0.0%)	2 (13.3%)	2 (14.3%)	0 (0.0%)	2 (13.3%)	$p = 0.347^a$
Implant's position:						
11	3 (20.0%)	0 (0.0%)	0 (0.0%)	0 (0.0%)	1 (6.7%)	$p = 0.719^a$
12	2 (13.3%)	0 (0.0%)	3 (20.0%)	2 (13.3%)	1 (6.7%)	
13	1 (6.7%)	0 (0.0%)	0 (0.0%)	0 (0.0%)	0 (0.0%)	
14	3 (20.0%)	3 (20.0%)	5 (33.3%)	3 (20.0%)	4 (26.7%)	
15	1 (6.7%)	1 (6.7%)	3 (20.0%)	2 (13.3%)	2 (13.3%)	
21	1 (6.7%)	1 (6.7%)	0 (0.0%)	1 (6.7%)	0 (0.0%)	
22	0 (0.0%)	1 (6.7%)	0 (0.0%)	0 (0.0%)	2 (13.3%)	
23	1 (6.7%)	0 (0.0%)	0 (0.0%)	0 (0.0%)	0 (0.0%)	
24	3 (20.0%)	5 (33.3%)	3 (20.0%)	3 (20.0%)	3 (20.0%)	
25	0 (0.0%)	1 (6.7%)	1 (6.7%)	1 (6.7%)	1 (6.7%)	
32	0 (0.0%)	1 (6.7%)	0 (0.0%)	0 (0.0%)	0 (0.0%)	
34	0 (0.0%)	0 (0.0%)	0 (0.0%)	1 (6.7%)	0 (0.0%)	
35	0 (0.0%)	1 (6.7%)	0 (0.0%)	1 (6.7%)	0 (0.0%)	
44	0 (0.0%)	0 (0.0%)	0 (0.0%)	1 (6.7%)	1 (6.7%)	
45	0 (0.0%)	1 (6.7%)	0 (0.0%)	0 (0.0%)	0 (0.0%)	
Augmentation hard tissue:						
Geistlich Bio-Oss®	9 (60.0%)	4 (26.7%)	4 (26.7%)	5 (33.3%)	2 (13.3%)	$p = 0.084^a$
Geistlich Bio-Gide®	9 (60.0%)	8 (53.3%)	5 (33.3%)	3 (20.0%)	5 (33.3%)	$p = 0.155^a$
Biotype thick clinical measurements	9 (60.0%)	11 (73.3%)	8 (53.3%)	10 (66.7%)	9 (60.0%)	$p = 0.830^a$
Total number of inserted implants	15 (20.0%)	15 (20.0%)	15 (20.0%)	15 (20.0%)	15 (20.0%)	
Patients receiving 1 implant	15 (100.0%)	13 (86.7%)	14 (93.3%)	12 (80.0%)	14 (93.3%)	
Patients receiving 2 implants	0 (0.0%)	2 (13.3%)	1 (6.7%)	3 (20.0%)	1 (6.7%)	

M – mean, SD – standard deviation, Me – median, Q_1 – lower quartile, Q_3 – upper quartile, Min – minimum, Max – maximum.

^a Chi-square test.

^b ANOVA.

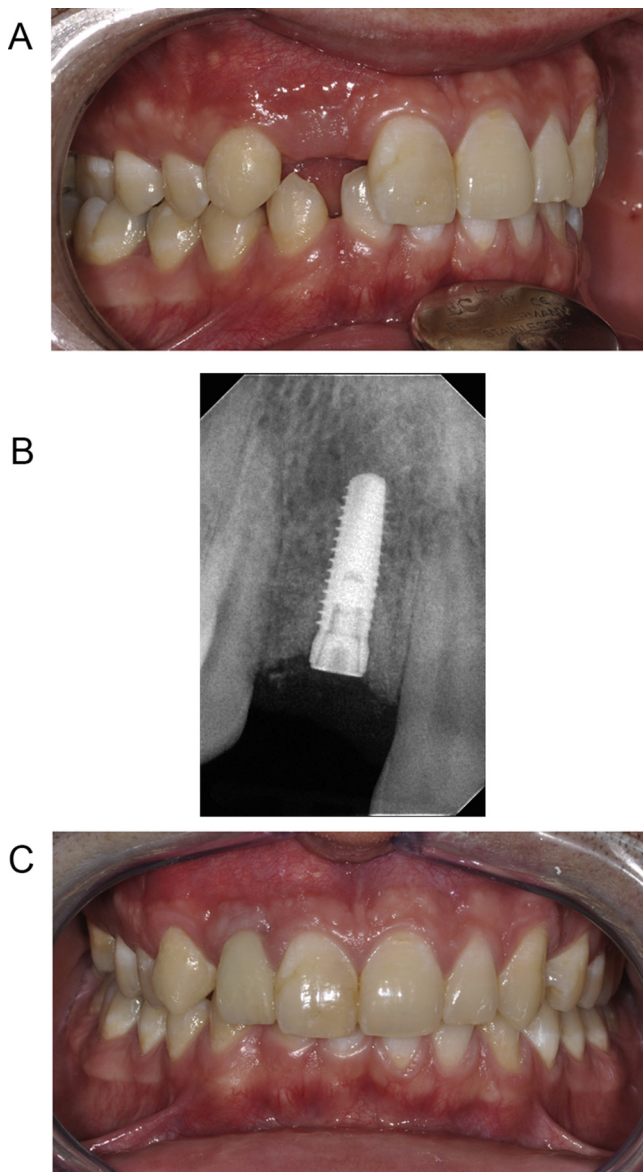


Fig. 1. (a) Initial clinical situation in group I (control). (b) Radiography after insertion of implant in region 12. (c) 12 months after implant insertion.

- implants placed with an insertion torque of 35 Ncm or less;
- fresh post extraction sockets;
- a smoking habit exceeding 10 cigarettes per day.

The protocol was approved by the Bioethics Committee of the Medical University of Wrocław (No. KB-217.2012). All patients were informed of the planned treatment, its possible consequences and had given their consent for the procedure to be performed by signing the informed consent. Only one of the investigators (MD), who was not involved in the selection and treatment of the patients, randomly assigned participants following simple randomization procedures to treatment groups (double blinded probe). The randomized codes were enclosed in sequentially numbered, identical, opaque, sealed envelopes. Envelopes were opened immediately after eligible patients were anaesthetized, therefore, treatment allocation was concealed to the investigators in charge of enrolling and treating the patients included in the trial.

In this study, a total number of 75 implants were inserted in 57 patients (34 women and 23 men) aged between 18 to 60 years. The main baseline patient characteristics are presented in [Table 1](#).

The patients were divided into 3 groups according to the gingival augmentation method used:

- without augmentation gingiva (control group).
- thickening of the soft tissue 3 months before implantation (test group).
- thickening of the soft tissue 3 months after implantation (test group).

Groups II and III were divided into two subgroups according to the material used:

- a) Geistlich Mucograft[®] collagen matrix.
- b) connective tissue graft.

Group I: total 15 single implants in 15 patients.

Group II: total 30 implants in 23 patients. Group II consisted of two subgroups.

Group II/Subgroup A: 15 implants in 13 patients (11 patients with single, 2 patients with double implants).

Group II/Subgroup B: 15 implants in 14 patients (13 patients with single and 1 patients with double implants).

Group III: total 30 implants in 22 patients. Group III consisted of two subgroups.

Group III/Subgroup a: 15 implants in 12 patients (9 patients with single, 3 patients with double implants).

Group III/Subgroup B: 15 implants in 14 patients (11 patients with single, 2 patients with double implants).

Bone level tapered implants Conelog[®], (Camlog[®] Biotechnologies AG, Switzerland) were inserted. The conical internal configuration of an implant in conjunction with Conelog[®] abutments allows for integrated platform switching. When the external lamina of the alveolar process required augmentation during implantation (to the first thread), deproteinized bovine bone mineral material (Bio-Oss[®], Geistlich Pharma AG, Switzerland) and a native bilayer collagen membrane (Bio-Gide[®], Geistlich Pharma AG, Switzerland) were used. Implant loading took place after 6 months. All implants were restored with metal-ceramic cemented crowns with semipermanent cement (Implantlink[®], Detax, Germany). All the procedures were carried out by the same researcher (MP) according to the adopted study protocol.

2.2. Clinical procedures

2.2.1. The surgical implantation procedure

All patients underwent at least one session of oral hygiene instruction and debridement if necessary in the 10 days prior to implant placement. Also they received a single dose of prophylactic antibiotic therapy 1 hour prior to implant placement: 2 g of amoxicillin, or 600 mg Clindamycin, if they were allergic to penicillin. The patients rinsed their oral cavities for 1 minute prior to implant placement with 0.2% chlorhexidine mouthwash (Eludril[®], Pierre Fabre Medicament, Boulogne, France).

The implantation of Conelog[®] implants was performed under local anaesthesia by Articain with adrenaline 1:100.000 (Ubistesin[®], 3M ESPE, Seefeld, Germany) using the limited flap technique (envelope flap). The surgical motor was set at a torque of 35 Ncm. Implants placed with an insertion torque of up to 35 Ncm were not included in the study. The implant shoulder position can be viewed in three dimensions:

- mesio-distal: at least 2 mm from neighbouring teeth and 3 mm between 2 implants.
- oro-facial: 2 mm of bone should be preserved starting from the tangent line of the neighbouring teeth on the buccal surface.

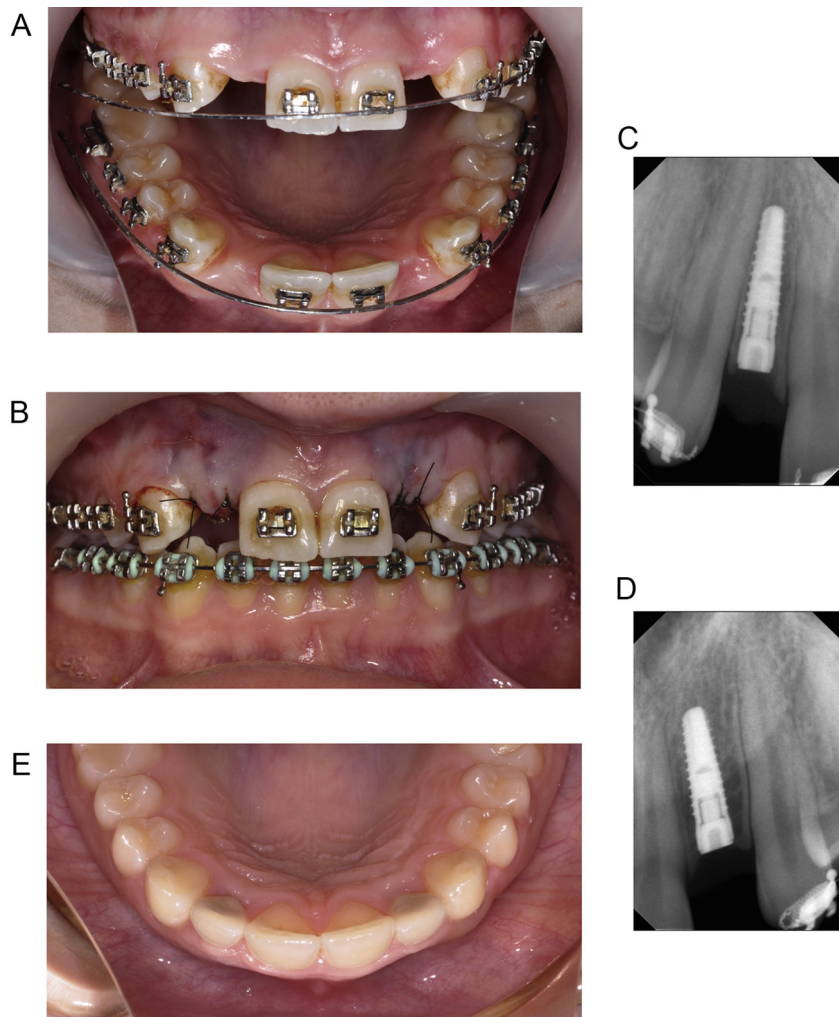


Fig. 2. (a) Initial clinical situation in-group II. (b) Intraoperative situation with soft tissue augmentation of connective tissue graft (CTG), in region 12 and xenogeneic collagen matrix (CMX) in region 22. (c) Radiography after insertion of implant in region 12. (d) Radiography after insertion of implant in region 22. (e) 12 months after soft tissue augmentation with CTG and CMX. Final restoration.

- corono-apical: at least 2–3 mm apically to the free gingival margin of the neighbouring teeth.

The mucoperiosteal flaps were closed and sutured with non-resorbable 5/0 suture (Seralene[®], Serag Wiessner, Germany) sutures. The patients were instructed to use chlorhexidine mouth-wash Eludril Classic[®] (Pierre Fabre Medicament, France) twice a day for 1 min for 2 weeks. The antibiotic Augmentin[®] (SmithKline Beecham Pharmaceuticals-Brentford) was administered twice a day for 6 days. 400 mg Ibuprofen (or 1 g paracetamol for patients with gastric problems or who were allergic to ibuprofen) was prescribed 3 times a day with meals for 3 days. The sutures were removed after 14 days and the patients received detailed oral hygiene instructions.

This procedure was carried out on all three groups. In case of groups I and III (Figs. 1a–c, 3a–c) the clinical procedure was started from implant placement and next soft tissue augmentation only for group III (Fig. 3d–f) and from soft tissue augmentation and next implant placement for group II (Fig. 2a–e).

2.3. The surgical procedure for soft tissue augmentation

2.3.1. Preparation recipient region

The procedures were performed using a local anaesthetic containing 4% articaine with adrenaline (Ubistesin[®], 3M ESPE, Seefeld,

Germany), which was administered with The Wand[™] (Milestone, USA). The first stage of the surgical procedure involved smoothing the adjacent tooth root using fine finishing burs (mechanical biomodification). The treatment was based on the “envelope technique” (Raetzke, 1985), without making vertical incisions. The donor site is prepared by creating a mucous flap or making a supra-osseous envelope. The incisions were made obliquely, diverting to the vestibular bottom without damaging the periosteum. A horizontal incision was made through the gingival sulcus. The facial portion of the interdental papilla in the surgical site was then de-epithelialized to achieve maximum contact for the connective tissue so as to facilitate aesthetic healing of the wound. The partial-thickness flap was elevated in an apical direction up to the mucogingival line. The periosteum was then cut and a blunt dissection into the vestibular lining mucosa was made to eliminate muscle tension so that the mucosal flap could be passively positioned at or slightly above the CEJ level on the adjacent teeth.

2.3.2. Preparing the donor site for the connective tissue graft

After administering local anaesthesia with The Wand[™], the subepithelial connective tissue graft was taken from the hard palate in the area between the first premolar and the first molar by making a single incision parallel to the gingival margin with a size 15c blade. The cut was made 3 mm from the edge of the gingiva without

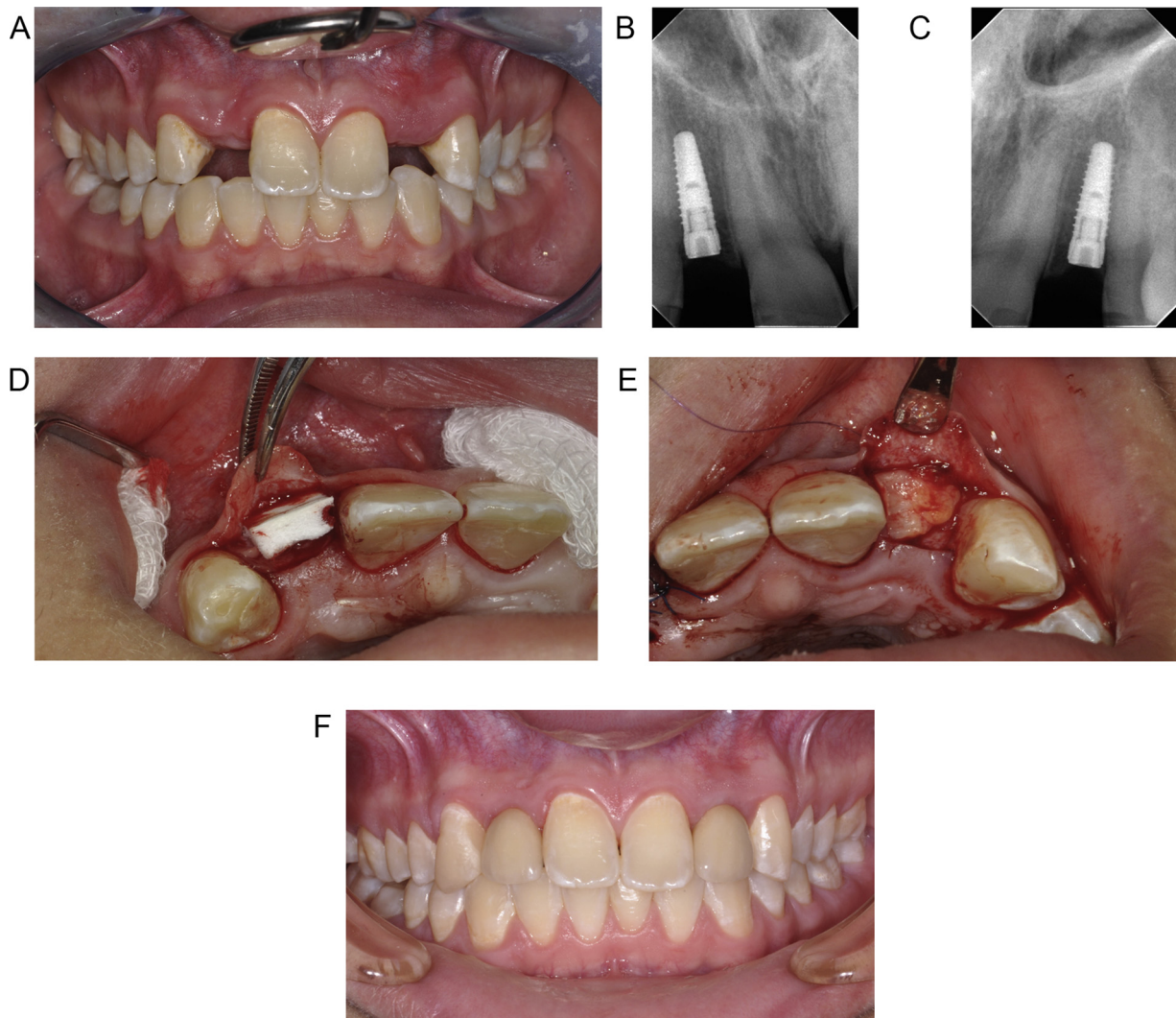


Fig. 3. (a) Initial clinical situation in-group III. (b) Radiography after insertion of implant in region 12. (c) Radiography after insertion of implant in region 22. (d) Intraoperative situation with soft tissue augmentation of CMX. (e) Intraoperative situation with soft tissue augmentation of CTG. (f) 12 months after soft tissue augmentation with CTG and CMX. Final restoration.

any contact with the bone. Next, a split flap was prepared parallel to the bone towards the middle of the palate. The final cut was made approximately 1.5 mm apically against the first cut. Then the graft was harvested from palate. The donor place was replaced by collagen (Biokol[®], Ravimed, Poland) and sutured (Seralon[®] 5/0; SeragWiessner, Naila, Germany). The graft was trimmed in such a manner that it was deprived of any fat tissue and other irregularities. It was then sutured to the recipient bed with periostitic sutures (Monosyn[®], Braun, Germany). Next, the graft was covered with a partial thickness flap, which was coronally repositioned.

2.3.3. Preparation of Geistlich Mucograft[®] collagen matrix

Geistlich Mucograft[®] was cut into a shape and size that corresponded to the surgical site, so that it would cover the site completely. The smooth side was turned towards the flap and the porous side towards the periosteal. The matrix was stabilized with mono-filament resorbable sutures with a thickness of 5-0 (Monosyn[®], Braun, Germany). It was stabilized on the periosteum on the vestibular side. The mucosal flap was then moved so as to completely cover the matrix. In turn, non-resorbable 5-0 sutures were used to stabilize the mucosal flap (Seralene[®], Serag Wiessner, Germany).

2.3.4. Outcomes measures

In all groups of patients, the thickness of keratinized tissue and gingiva biotype were measured. TKT was measured using ultrasonography with a Piroop[®] dental, ultrasound device (Echson Company, Poland) (Bednarz, 2011) (Fig. 4a). The validation of this equipment was performed in experimental and clinical studies (Slak et al., 2015; Bednarz and Zieliniska, 2011).

The Piroop[®] Ultrasonic Biometer features an A-scan probe with a 20 MHz frequency and is designed to measure soft tissue thickness in the range 0.25–6 mm, and with an accuracy of up to 0.01 mm. The round front of the tapered head is 1.7 mm in diameter and allows measurements to be taken in difficult locations. The 45° angle between the probe's handle and the tip allows for precise positioning of the head at a 90° angle with respect to the bone base. The ultrasound head is located in the examined region. It is placed in contact with the mucosa, but without applying pressure (Fig. 4b). The duration of the return of the ultrasonic impulse echo in a single measurement is calculated to distance and passes at a velocity of 1540 m/s; i.e. the thickness of the examined mucosa. The return of the impulse and the consequent procurement of the result are impossible when the head is not positioned perpendicularly to the base. The device measures mucosa thickness and also calculates the arithmetic mean. In addition, in this study, gel (Elugel[®],

Table 2
Thickness of keratinized gingiva in different groups according to times of augmentation.

Groups	Point 1 – CEJ									
	TKT-0			TKT-3			TKT-12			
	M (mm)	SD	Min–Max	M (mm)	SD	Min–Max	M (mm)	SD	Min–Max	
I	1.39	±0.65	0.56–2.42	1.62	±0.50	0.91–2.62	2.10	±0.66	0.90–2.83	
Ila	1.30	±0.46	0.86–2.61	1.74	±0.37	1.06–2.42	2.46	±0.75	1.43–3.90	
Ilb	1.30	±0.23	1.02–1.74	2.19	±0.55	1.15–3.03	3.06	±0.61	2.09–3.97	
IIa	1.21	±0.49	0.53–2.20	1.83	±0.83	1.11–3.53	2.10	±0.50	1.15–3.32	
IIb	1.15	±0.40	0.53–2.05	2.10	±0.77	1.15–3.83	2.68	±0.96	1.61–5.51	
Point 2 – MGJ										
I	1.10	±0.44	0.37–1.88	1.31	±0.41	0.65–2.02	1.46	±0.34	1.06–2.24	
Ila	1.04	±0.47	0.32–2.34	1.43	±0.56	0.36–2.51	2.04	±0.61	0.92–2.99	
Ilb	0.75	±0.26	0.36–1.40	1.39	±0.48	0.45–2.36	2.11	±0.70	0.86–3.41	
IIa	1.01	±0.41	0.38–1.97	1.48	±0.44	1.00–2.50	1.57	±0.52	0.71–2.71	
IIb	0.90	±0.30	0.45–1.38	1.91	±0.78	1.09–3.81	2.05	±0.56	1.15–3.11	

TKT – thickness of keratinized tissue, TKT-0 – prior to implant placement, TKT-3 – 3 months post augmentation, TKT-12 – 12 months post augmentation, CEJ – cemento-enamel junction, MGJ – mucogingival junction, M – mean, SD – standard deviation, Min – minimum, Max – maximum.

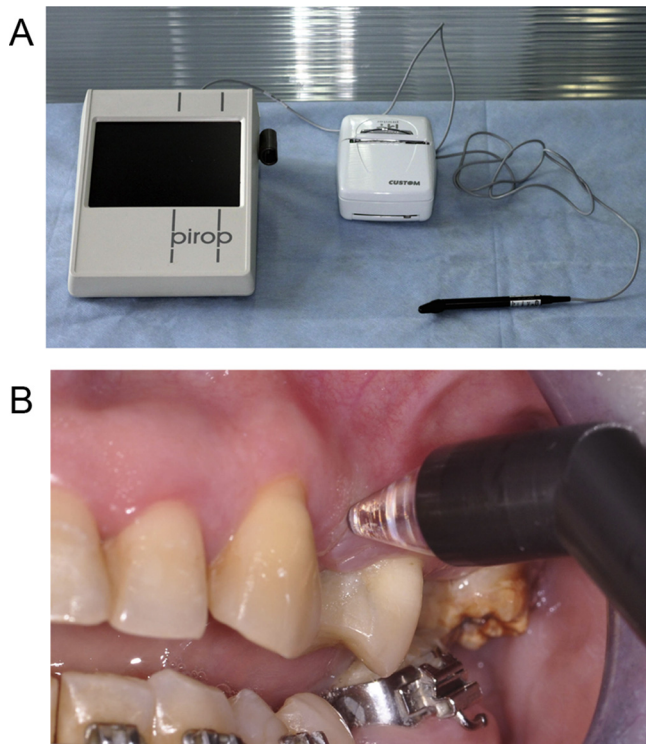


Fig. 4. (a) Pirop[®] ultrasound equipment. (b) The measurement of keratinized gingiva in point 1 using Pirop[®] device.

Pierre Fabre Medicament, Boulogne, France) was used as lubricant to examine ultrasound.

Measurements were taken prior to, then 3 and 12 months after soft tissue augmentation. The timeline of measurements for all groups is presented in Fig. 5. The thickness of the keratinized gingiva was measured at two points:

- 1) the 1st point on the line, connecting the cemento-enamel junctions (CEJs) of both adjacent teeth on the gingival margin (Fig. 4b). When 2 adjacent teeth were missing, each point was measured separately for each implant on the gingival margin.
- 2) the 2nd point on the mucogingival junction (MGJ) along the axis of the future implant.

Follow-ups were conducted by an independent blinded outcome assessor (AB).

2.3.5. Gingival biotype

The gingiva biotype of each studied implant was evaluated and classified as a thick or a thin biotype. The biotypes were assessed with a periodontal probe (UNC, Hu-Friedy, Chicago, IL, USA) at the first appointment. They were placed in the gingival sulcus on the facial aspect of the adjacent tooth. The biotype was categorized as thin if the outline of the underlying periodontal probe could be seen through the gingiva, and thick if the probe could not be seen (Kan et al., 2010). Each examination was performed by the same researcher (MP).

2.3.6. Statistical analysis

The data were analysed using the Chi-square Test and ANOVA statistical software. The results of multiple comparisons regarding changes in keratinized gingiva height were based on the post-hoc test (Tukey test). *T-Student* was used to estimate gingival biotype. The mean differences were considered to be statistically significant at $p > 0.05$.

3. Results

The present article is reported according to the CONSORT (Consolidated Standards of Reporting Trials) statement for improving the quality of reports of parallel-group randomised trials (Schulz et al., 2011) (Fig. 6).

In this study, 75 implants were inserted in 57 patients (34 women and 23 men) aged between 18 to 60 years. The main baseline patient characteristics are presented in Table 1.

Fifteen implants were inserted in each group/subgroup:

- 15 single implants in 15 patients
- 30 implants in 23 patients
 - a. 15 implants in 13 patients (11 patients with single, 2 patients with double implants)
 - b. 15 implants in 14 patients (13 patients with single and 1 patients with double implants)
- 30 implants in 22 patients
 - a. 15 implants in 12 patients (9 patients with single, 3 patients with double implants)
 - b. 15 implants in 14 patients (11 patients with single, 2 patients with double implants).

All patients experienced uneventful healing in the surgical area. The overall survival rate for the 75 Conelog[®] implants, 30 connective tissue grafts and 30 Geistlich Mucograft[®] collagen matrices in a 1-year follow-up was 100% for the group as a whole. Intraoperative or postoperative complications including bleeding, necrosis

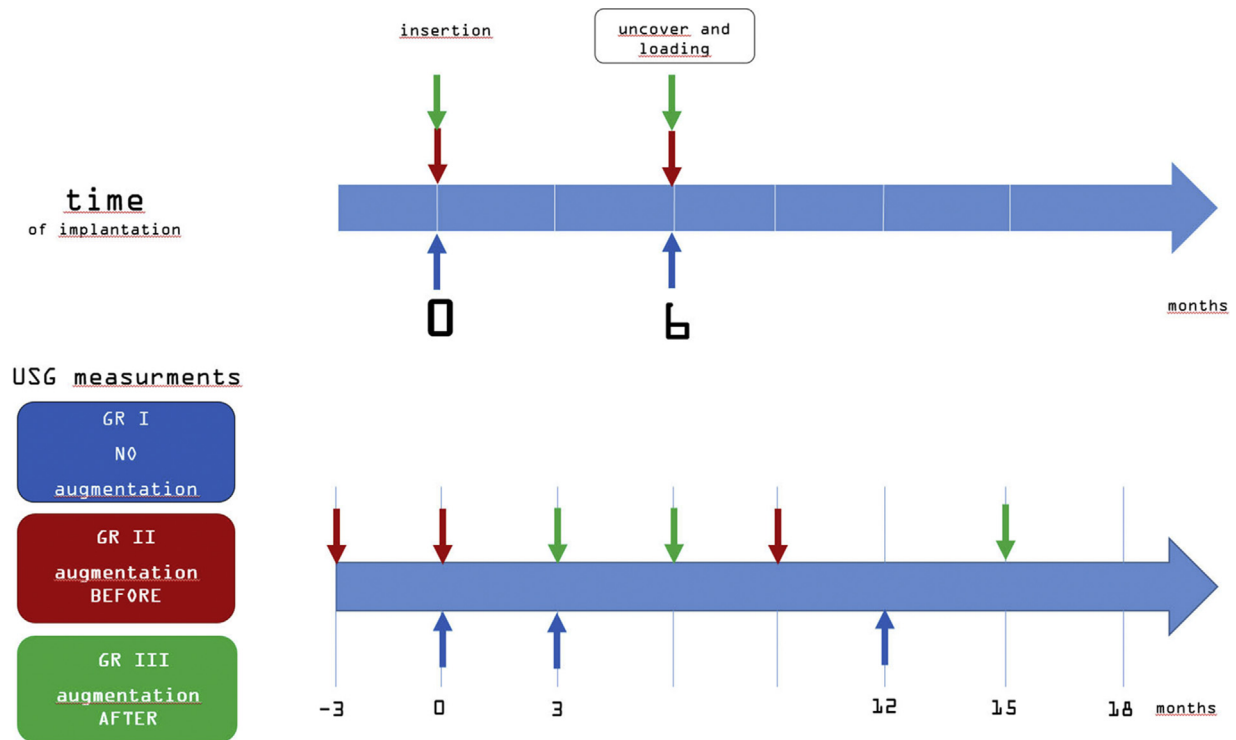


Fig. 5. Timeline of research (arrows present the assessment of thickness gingiva with USG, blue in control group I, red in group II, green in group III). (For interpretation of the references to colour in this figure legend, the reader is referred to the web version of this article.)

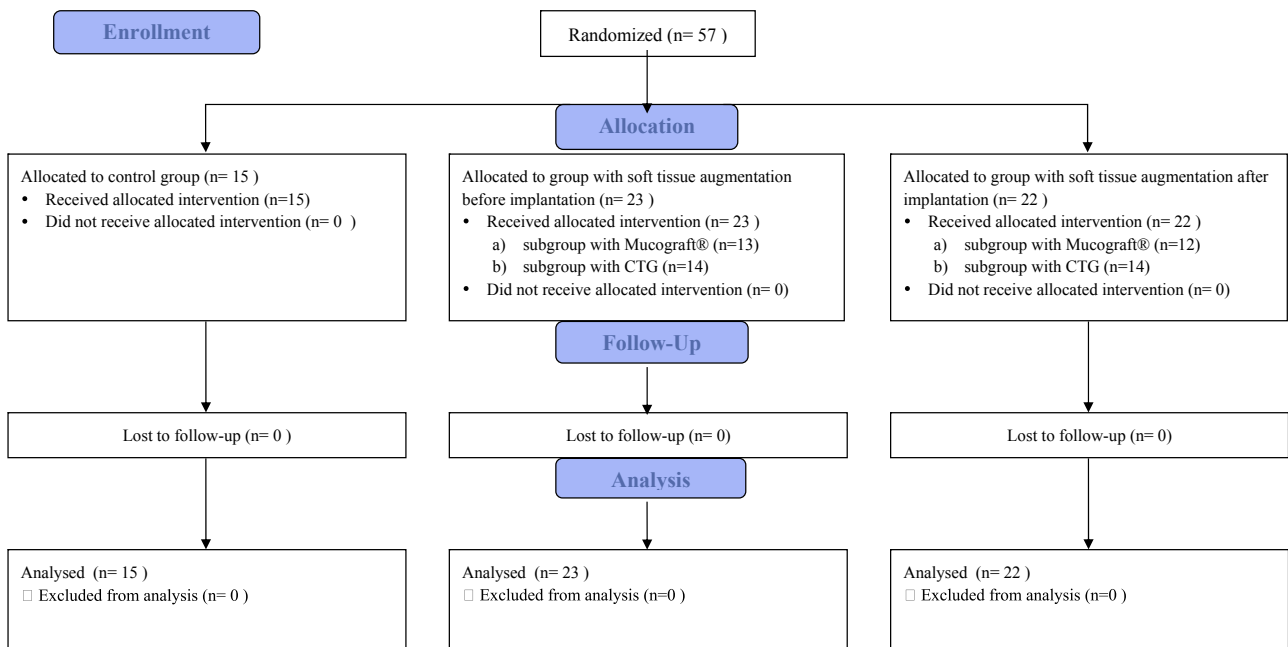


Fig. 6. Consort 2010 flow diagram.

and abnormal swelling occurred neither at the recipient nor at the donor site. No prosthetic complications were recorded in follow-up visits.

3.1. Assessment of thickness of keratinized gingiva (TKT) with ultrasonography

Measurements of thickness of KT after enrolling patient to the study, prior to surgery, indicated that the average value of TKT in

all groups was below 2 mm (Table 2). Mean values of TKT at point 1 were between 1.15 ± 0.40 to 1.39 ± 0.65 and at point 2 – 0.9 ± 0.77 to 1.10 ± 0.44 . There was no SS difference between all groups in case of point 1 and 2.

3.1.1. Intergroup analysis

3.1.1.1. Ultrasonic assessment after 3 months. At point 1 a significant difference in thickness gain (Tables 3 and 4) was observed only between groups I and IIIb (0.23 mm vs. 0.95 mm; $p = 0.042 < 0.05$).

Table 3
Basic statistics of the keratinized gingiva thickness changes in ultrasonography at points 1 and 2 in the compared groups of patients and the results of the comparisons.

Change of the gingival thickness Δ GT (mm)	Group I N=15	Group IIa CMX prior to implant N=15	Group IIb CTG prior to implant N=15	Group IIIa CMX after to implant N=15	Group IIIb CTG after to implant N=15	Test
After 3 months – point 1						
<i>M</i> \pm <i>SD</i>	0.23 \pm 0.6	0.44 \pm 0.6	0.89 \pm 0.6	0.62 \pm 0.9	0.95 \pm 0.7	$p = 0.028^a$
<i>Me</i> (Q_1 ; Q_3)	0 (0; 1)	1 (0; 1)	1 (0; 2)	1 (0; 1)	1 (1; 1)	
<i>Min</i> \div <i>Max</i>	-1 \div 1	-1 \div 1	0 \div 2	-1 \div 2	0 \div 3	
After 3 months – point 2						
<i>M</i> \pm <i>SD</i>	0.21 \pm 0.4	0.38 \pm 0.5	0.64 \pm 0.5	0.48 \pm 0.4	1.01 \pm 0.7	$p = 0.001^a$
<i>Me</i> (Q_1 ; Q_3)	0 (0; 0)	0 (0; 1)	1 (0; 1)	1 (0; 1)	1 (0; 2)	
<i>Min</i> \div <i>Max</i>	-1 to 1	0-1	0-2	0-1	0-3	
After 12 months – point 1						
<i>M</i> \pm <i>SD</i>	0.7 \pm 0.8	1.16 \pm 0.7	1.76 \pm 0.7	0.89 \pm 0.6	1.52 \pm 1.0	$p = 0.002^a$
<i>Me</i> (Q_1 ; Q_3)	0 (0; 2)	1 (1; 2)	2 (1; 2)	1 (0; 1)	1 (1; 2)	
<i>Min</i> \div <i>Max</i>	-1 to 2	0-3	0-3	0-2	0-4	
After 12 months – point 2						
<i>M</i> \pm <i>SD</i>	0.35 \pm 0.6	1.0 \pm 0.7	1.36 \pm 0.6	0.57 \pm 0.6	1.15 \pm 0.5	$p < 0.001^a$
<i>Me</i> (Q_1 ; Q_3)	0 (0; 1)	1 (0; 2)	1 (1; 2)	1 (0; 1)	1 (1; 2)	
<i>Min</i> \div <i>Max</i>	-1 to 2	0-2	0-2	-1 to 2	0-2	

M – mean, *SD* – standard deviation, *Me* – median, Q_1 – lower quartile, Q_3 – upper quartile, *Min* – minimum, *Max* – maximum.

^a ANOVA.

Table 4

Results of the multiple comparison of the gingiva thickness changes in ultrasonography after 3 months at point 1, via the post-hoc test (the Tukey test).

	Group IM = 0.23 mm	Group IIaM = 0.44 mm	Group IIbM = 0.89 mm	Group IIIaM = 0.62 mm	Group IIIbM = 0.95 mm
Group I	×	$p = 0.915$	$p = 0.074$	$p = 0.529$	$p = 0.042$
Group IIa	$p = 0.915$	×	$p = 0.387$	$p = 0.953$	$p = 0.267$
Group IIb	$p = 0.074$	$p = 0.387$	×	$p = 0.816$	$p = 0.999$
Group IIIa	$p = 0.529$	$p = 0.953$	$p = 0.816$	×	$p = 0.686$
Group IIIb	$p = 0.042$	$p = 0.267$	$p = 0.999$	$p = 0.686$	×

Table 5

Results of the multiple comparison of the gingiva thickness changes in ultrasonography after 3 months at point 2, via the post-hoc test (the Tukey test).

	Group IM = 0.21 mm	Group IIaM = 0.38 mm	Group IIbM = 0.64 mm	Group IIIaM = 0.48 mm	Group IIIbM = 1.01 mm
Group I	×	$p = 0.890$	$p = 0.165$	$p = 0.620$	$p = 0.001$
Group IIa	$p = 0.890$	×	$p = 0.654$	$p = 0.987$	$p = 0.010$
Group IIb	$p = 0.165$	$p = 0.654$	×	$p = 0.910$	$p = 0.272$
Group IIIa	$p = 0.620$	$p = 0.987$	$p = 0.910$	×	$p = 0.042$
Group IIIb	$p = 0.001$	$p = 0.010$	$p = 0.272$	$p = 0.042$	×

At point 2, on the MGJ, gingival thickness increased significantly (Tables 3 and 5) in both the CTG group (IIIb) and the Geistlich Mucograft® group (IIIa), but the higher value was achieved in group CTG. Significant differences in thickness gain between groups I–IIIb, IIa–IIIb and IIIa–IIIb were also observed. The range of HKT gain was on the level 0.38 mm to 0.8 mm. The highest value was in case of I–IIIb group – 0.80 mm (0.21 mm vs. 1.01 mm; $p = 0.001 < 0.01$) and next for IIIa–IIIb (0.48 mm vs. 1.01 mm; $p = 0.042 < 0.05$) and IIa–IIIb (0.38 mm vs. 1.01 mm; $p = 0.010 < 0.05$).

3.1.2. Ultrasonic assessment after 12 months. At point 1 the high mean TKT value was recorded in CTG groups: IIb and IIIb (Tables 3 and 6), but the highest value (1.76 mm) was in the group IIb (CTG before implantation). The lowest value in this respect was observed in CMX group after implantation-IIIa (0.89 mm). There was also a significant difference in gingival thickness gain between control groups I and IIb, which amounted on average to 1.06 mm, and as follows IIb and IIIa (0.87 mm) and I and IIIb (0.82 mm). There was no significant statistical difference at point 1 after 12 months between the groups where the same material was used. Comparisons of the increase in the thickness of keratinized gingiva after 12 months in different groups in relation to time of augmentation is presented in Fig. 7.

At point 2 the highest mean value was observed also in group IIb-CTG before implantation (1.36 mm), followed by group CTG after implantation-IIIb (1.15 mm), groups CMX-before-IIa (1.00 mm)

and after-IIIa (0.57 mm). Significant differences in gingival thickness gain were also observed between control groups I and IIb (1.01 mm), as well as I and IIIb (0.8 mm). Likewise, there were considerable differences between groups I and IIa (0.65 mm) as well as between groups IIb and IIIa (0.79 mm) (Tables 3 and 7).

NSSD were noted between groups which were augmented by the same material independently on time of augmentation.

3.1.3. Intragroup analysis

In the intragroup analysis for CMX groups (a), the highest difference in keratinized gingiva gain between 3 and 12 months was observed in group II. This difference was 0.8 mm ($p = 0.006 < 0.01$). In CTG groups (b), better results were observed also in group II. The mean increase in gingival width was 0.9 mm after 3 months and 1.8 mm after 12 months. The difference in width gain after 3 and 12 months was on the level of 0.9 mm SSD ($p = 0.006 < 0.01$). In group III was NSSD 0.6 mm.

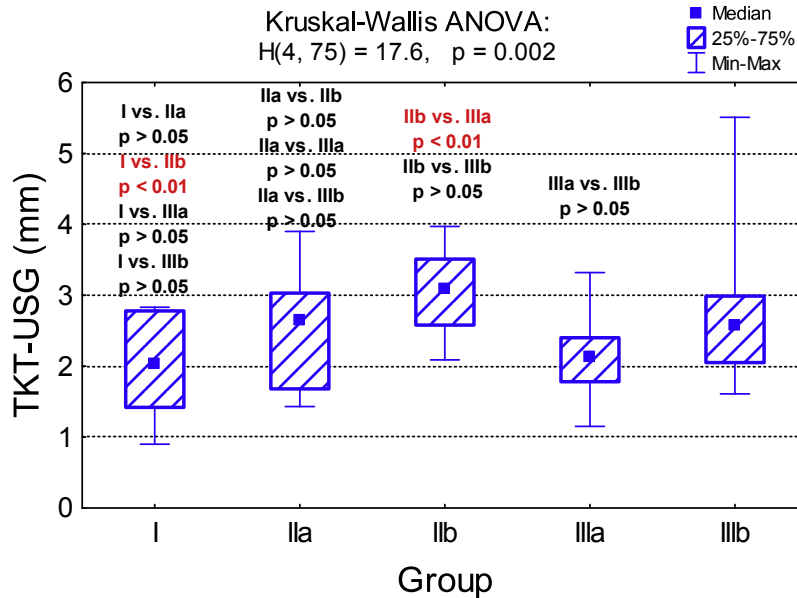
3.1.4. Gingival biotype

Based on a clinical presurgical measurement with a periodontal probe, the biotype was estimated by an examiner as thick. However more accurate and detailed ultrasound examination did not confirm the clinical estimation. The ultrasound measurement of TKT indicated that all of the patients had thin biotype because the average value of KG was below 2 mm (Table 2). Before implant insertion, only in group IIb, 3 months after soft tissue thickening,

Table 6

Results of the multiple comparison of the gingiva thickness changes in ultrasonography after 12 months at point 1, via the post-hoc test (the Tukey test).

	Group IM = 0.70 mm	Group IIaM = 1.16 mm	Group IIbM = 1.76 mm	Group IIIaM = 0.89 mm	Group IIIbM = 1.52 mm
Group I	×	$p = 0.511$	$p = 0.004$	$p = 0.967$	$p = 0.043$
Group IIa	$p = 0.511$	×	$p = 0.241$	$p = 0.880$	$p = 0.710$
Group IIb	$p = 0.004$	$p = 0.241$	×	$p = 0.028$	$p = 0.928$
Group IIIa	$p = 0.967$	$p = 0.880$	$p = 0.028$	×	$p = 0.188$
Group IIIb	$p = 0.043$	$p = 0.710$	$p = 0.928$	$p = 0.188$	×

**Fig. 7.** Comparison of the increase in the thickness of keratinized gingiva after 12 months in different groups in relation to time of augmentation.**Table 7**

Results of the multiple comparison of the gingiva thickness changes in ultrasonography after 12 months at point 2, via the post-hoc test (Tukey test).

	Group IM = 0.35 mm	Group IIaM = 1.00 mm	Group IIbM = 1.36 mm	Group IIIaM = 0.57 mm	Group IIIbM = 1.15 mm
Group I		$p = 0.012$	$p < 0.001$	$p = 0.327$	$p < 0.001$
Group IIa	$p = 0.012$		$p = 0.165$	$p = 0.091$	$p = 0.497$
Group IIb	$p < 0.001$	$p = 0.165$		$p = 0.002$	$p = 0.323$
Group IIIa	$p = 0.327$	$p = 0.091$	$p = 0.002$		$p = 0.006$
Group IIIb	$p < 0.001$	$p = 0.497$	$p = 0.323$	$p = 0.006$	

biotype was changed from thin to thick. Furthermore 12 months after soft tissue augmentation in all groups of patients, a thick biotype, due to increase TKT above 2 mm was observed (Table 2; Fig. 7).

4. Discussion

The results of this prospective clinical study have demonstrated the effectiveness of soft tissue augmentation around implants using a connective tissue graft and a Geistlich Mucograft® collagen matrix. The augmentation procedure was more effective in changing the thickness of keratinized gingiva when compared to patients without soft tissue augmentation. Nevertheless, the best results were obtained in case of thickening soft tissue using CTG.

Subepithelial connective tissue graft and split-thickness flap for patients with implants placed in the anterior, aesthetic area is recommended in order to, e.g. ensure the colour of the treated area which is uncertain in terms of loose structure of such tissue, because it contains a large amount of elastic fibres. That is why, in order to increase keratinized gingival width and thickness, the recommended approach is mainly to use connective tissue grafts inserted via grafts harvested using the Zucchelli et al. (2010)

technique. These grafts contain a larger amount of densely packed connective tissue fibres which are responsible for increasing the height and volume of keratinized gingiva. Subepithelial connective tissue grafts consisting of submucosal tissue rich in elastic fibre is rather responsible for increasing thickness, not width of soft tissue (Sculan et al., 2014). Therefore the choice of subepithelial connective tissue in our own study was based on similarity of the collagen matrix. The task was to assess to what extent similar substitutes/tissues increase the thickness of keratinized gingiva. Comparative assessment of gingival augmentation efficacy based on literature is presented in Table 8.

In the literature, GM was used in different treatment approaches to change soft tissue volume. Mostly it has been used to increase soft tissue width e.g. Lorenzo used Geistlich Mucograft® to increase keratinized gingiva height around implants via the vestibular deepening method (Lorenzo et al., 2012). In a 6-month follow-up the mean amount of KT gain for test group (Geistlich Mucograft®) compared with 12 patients from CTG control group was at the same level 2.30 mm vs. 2.33 mm (NSSD). Froum et al. (2015) made use of a collagen matrix simultaneous to immediate implantation. A full thickness flap was created before implant placement. TKT was measured three months after the surgery. The NSSD was noted

Table 8
Comparative assessment of gingival augmentation efficacy based on literature.

Author, year of publication	Number of patients/implants	Implant location	Time of augmentation	Methods of augmentation	Material of augmentation/value	Time of follow up	Methods of TKT measurements
roum et al. (2015)	31 patients	Single implants in the posterior area	At the time of implant surgery	Full thickness flap	CMX TKT – 1.8 mm Gain 0.74 mm	3 months	Extent of KT and the underlying bone by sounding with a silver point
runder (2011)	24 patients	Single implants in the anterior maxilla	At the one time of tooth extraction and implant surgery	Tunnel technique	CTG Gain 0.34 mm	6 months	A periodontal probe perpendicular to the long axis
roni et al. (2010)	14 patients/14 implants	Posterior and anterior area (type of jaws-unclear)	At the time of uncovering of implant and healing screw placement Unclear	Split-thickness flap	CTG/FGG 8 months – 1.75 mm 36 months – 1.4 mm	8, 36 months	A periodontal probe using customized acrylic stents
hallhorn et al. (2015)	30 patients/ 35 implants (post op-31 implants)	Unclear	Unclear	Interpositional graft on the buccal aspects, split-thickness flap	CMX TKT-3 months – 2.2 mm TKT-6 months – 2.2 mm (gain 0.7 mm) CTG TKT – 2.48 mm Gain – 0.83 mm	3, 6 months	An endodontic probe positioned approx. 1.5 mm apically to the gingival margin
ghbali et al. (2014)	10 patients	Single implants in the anterior maxilla	3 months after implant surgery	Envelope technique, split-thickness flap	CTG TKT – 2.48 mm Gain – 0.83 mm	9 months	Ultrasonic device (Epoch® 600, Olympus, Aartselaar, Belgium) – 5 MHz, 1516 m/s,
iesner et al. (2010)	10 implants	Posterior area of the mandible	At the time of implant surgery	Split-thickness flap	CTG TKT – 3.20 mm Gain 1.2 mm	12 months post loading	An endodontic micro-opener with silicon stop, 1 cm below the centre of the crest
e Bruyckere et al. (2015)	37 patients	Single implants in the anterior maxilla	3 months after implant surgery	Envelope technique, split-thickness flap	CTG 3 months – 2.60 mm (gain – 1.09 mm), 9 months – 2.50 mm (gain – 0.97 mm)	3, 9 months post soft tissue augmentation	Lower border at the level of the free mucosal margin – ultrasonic device (Epoch®, Olympus, Aartselaar, Belgium) – 5 MHz, 1516 m/s
Own study (2017)	57 patients/75 implants	Single implants in the anterior maxilla and mandible	3 months before (II group) and 3 months after (III group) implant surgery	Envelope technique, split-thickness flap	CMX (group a)/CTG (group b), gain – point 1 3 months – IIa – 0.44 mm, IIb – 0.89 mm; IIIa – 0.62 mm, IIIb – 0.95 mm 12 months – IIa – 1.16 mm, IIb – 1.76 mm, IIIa – 0.89 mm, IIIb – 1.52 mm	3, 12 months after soft tissue augmentation	Ultrasonic device (Piro® Echoston Company, Poland) – 20 MHz, 1540 m/s

TKT – thickness of keratinized tissue, CMX – Collagen Matrix Mucograft®, CTG – connective tissue garft.

between the Geistlich Mucograft[®] and the control group. The different surgical techniques may have contributed to this result. In the present study, partial-thickness flaps were used to create an envelope. A connective tissue graft was taken from the palate using the “single incision” method. Moreover, soft tissue augmentation was carried out before and after implantation. Other researchers also performed gingival augmentation but with immediate implantation to prevent subsidence of the soft tissue (Ouhayoun et al., 1988; Froum et al., 2015; Grunder, 2011). In one study, Grunder (2011) applied CTG at one time and, after 6 months, observed a mean TKT increase of 0.34 mm whereas Froum et al. (2015) observed a TKT gain between pre-surgery and 3 months post-surgery of 0.74 mm ± 0.78 mm in favour of the Geistlich Mucograft[®] group. The difference was statistically significant ($p = 0.009$). These short term findings can be a result of methods of soft tissue thickness measurements as the distance between the outer extent of KT and the underlying bone was carried out by sounding with a silver point. In the present study, a short-term assessment 3 months after soft tissue augmentation based on an ultrasound analysis showed a gain for Geistlich Mucograft[®] at points 1 – 0.4 mm ± 0.6 mm and 2 – 0.4 mm ± 0.5 mm for groups IIa and IIIa – 1–0.6 mm ± 0.9 mm and 2 – 0.5 mm ± 0.4 mm. Better results, but NSS were observed for group IIIa probably because of the lack of additional surgical procedures on previously augmented soft tissue. However, the statistical difference in the gain of keratinized gingiva was achieved only in group IIb. Also it should be stressed that all patients in our own study have thin biotype. These results are based on ultrasound measurements. In case of clinical measurements assessing biotype based on visible or not visible periodontal probe by the gingiva in sulcus of neighbouring teeth most patients were in thick biotype. So, in the context of assessment of soft tissue, this method seems to be inaccurate. Froum et al. also reported a significant increase in TKT with a thin biotype in 3 months follow-up. Moreover, similar results were achieved in a study by Speroni et al. (2010), which assessed the stability of gingival grafts around implants in a 36-months follow-up. Eight months after grafting, the mean increase in KT thickness was 1.75 mm, which declined to 1.4 mm at 36 months postoperatively. The change from the 12–36 month follow-ups was NSSD. This study implied that the biotype was the strongest predictor of increased KT, with the thin biotype showing a greater increase in KT as compared to the thick biotype. The possible explanation might be the fact that a gingival thin phenotype starts with an unfavourable local situation in comparison with its thick counterpart.

In case of Geistlich Mucograft[®], Schallhorn et al. (2015) applied it around implants in a multicentre pilot study. The xenogeneic collagen matrix was placed as an interpositional graft on the buccal aspects. The time of soft tissue augmentation is unclear. Gingival thickness was assessed for 35 implants placed in 30 patients using an endodontic probe positioned approx. 1.5 mm apically to the gingival margin. The measurements were assessed 3 and 6 months postoperatively. The mean increase in tissue thickness in 31 implants was 0.7 mm ± 0.8 mm ($p < 0.0001$) after 6 months. Similar results were obtained after 3 months postoperatively. In comparison with our study, the mean gain in soft tissue thickness using Geistlich Mucograft[®] was nearly the same. We achieved 0.89 mm ± 0.6 mm at point 1 and 0.57 mm ± 0.6 mm at point 2 in the case of group IIIa (CMX 3 month after implantation). However, in 12 months follow-up the gingival thickness was significantly higher in group IIa when soft tissue augmentation had been performed before implantation. The mean gain in soft tissue thickness was 1.16 mm ± 0.7 mm at point 1 and 1.0 mm ± 0.7 mm at point 2.

Other researchers measured soft tissue thickness with conventional impressions, which were optically scanned. Akcali et al. (2015) observed some shrinkage of the free connective tissue grafts 6 months after augmentation. The mean shrinkage amounted to

almost half of the volume (47%) between 3 and 6 months. Impressions were taken with silicon material. Models were cast in dental stone. All the stone models were digitized using a labased optical scanner. This method makes it possible to assess the soft tissue. Thoma et al. (2010) used the same methods to assess the volume of soft tissue in chronic ridge defects.

Also, a collagen matrix (CM) and CTG were used in an animal-based study. In a follow-up 84 days after the procedure, mean gains of 1.4 mm (CM; ±1.1) and 1.4 mm (CTG; ±0.4) were observed. The researchers observed that the mean shrinkage in soft tissue volume between 28 and 84 days was slightly higher for the collagen based matrix (CM) group (10%) than for the CTG group (5.7%) with no SS difference between the two groups ($p > 0.05$). Previous publications featured analyses of stone casts for the purpose of examining soft tissue changes during observations. Although this method makes it possible to compare data from different studies and time points, the accuracy of this procedure affects the quality of the impression and cast fabrication as well as the presence of stable reference points. Moreover, this approach is time-consuming.

In a recent study, Eghbali et al. (2016) used an ultrasonic device to assess TKT in a credible way. Nine months after soft tissue augmentation using CTG, an increase in KT (0.83 mm) was observed. However, this disparity could be explained by differences resulting from the use of other devices with different parameters, assessment periods, CTG time points (3 months after implantation at the site of the provisional crown installation) and location of points on the gingiva, depending on the implant location. In addition, Eghbali et al. (2016) assessed the precision and accuracy of gingival thickness registration. It was recorded with an ultrasonic device (Epoch[®] 600, Olympus, Aartselaar, Belgium) with a measurement frequency of 5 MHz and compared to tomography as registered with Micro-CT, taking the latter as the gold standard. They showed a strong correlation between ultrasonic and Micro-CT results ($r = 0.89$, $p < 0.001$), indicating considerable accuracy. Compared with our studies, the sample sizes presented in these cases were limited. Wiesner et al. (2010) placed only 10 implants in the posterior area, while Speroni et al. (2010) studied 14 patients, but implant location here is unclear. Meanwhile, in a study conducted by Eghbali et al. (2016), 10 patients were treated with single implants in the anterior maxilla. This study showed that soft tissue augmentation is imperative from an aesthetic point of view as it is the buccal soft tissue volume that provides the ideal emergence profile, hereby creating the illusion of a natural tooth. On the other hand, it showed that one limitation of ultrasonic determination of soft tissue thickness is the two-dimensional reproduction of three-dimensional changes. In the final study, De Bruyckere et al. (2015) examined 37 patients with single implants in the anterior maxilla. They used CTG 3 months after implant surgery and after the patient had been provided with a provisional crown. Mucosal thickness increased significantly; i.e. by 1.07 mm. It was measured immediately after soft tissue augmentation. Gingival thickness was measured by means of an ultrasonic device (Epoch[®], Olympus, Aartselaar, Belgium). The probe was positioned with its lower border at the level of the free mucosal margin. Ultrasonic pulses were transmitted through the sound permeable mucosa at 1516 m/s, which is very similar to the sound velocity of the device used in the present study (1540 m/s). Differences were observed in the frequency of the devices (5 MHz vs. 20 MHz). De Bruyckere et al. (2015) observed a mean increase in mucosal thickness 0.97 mm ± 0.48 mm 1 year after implant placement (9 months after CTG). Hence, the mean soft tissue loss amounted to 0.10 mm ± 0.23 mm. It is interesting to note that this mean was slightly lower than the results in the present study for group III for which a CTG was used 3 months after implantation. The mean KT thickness gain was 1.52 mm ± 1.0 mm at the first point and the average gingival increase was 1.15 mm ± 0.5 mm at the sec-

ond point. One possible explanation for this could be the difference at the measured points, in the frequency of the ultrasonic device and in the measured period of time. In addition, De Bruyckere et al. (2015) observed no statistical differences in soft tissue gain between patients with thin or thick biotypes.

Based on this discussion there are many apparent difficulties in making a proper assessment of the thickness of KT. Definitely standardized, accurate, non-time-consuming and repeatable methods should be used. Also, the proper times of measurements of soft tissue for each respective augmentation procedure should be established. The lack of such regulations makes suitable comparison between different investigations impossible.

5. Conclusions

1. Pirop® – an ultrasonic device is a non-invasive, reliable and reproducible method for evaluating soft tissue.
2. The most convenient time to carry out a gingival augmentation procedure should be before implant placement.
3. Geistlich Mucograft® offers an alternative method to connective tissue grafts in gingival augmentation procedures, but with a lower value of soft tissue increase.
4. Soft tissue augmentation before implant placement combined with the connective tissue graft is the most efficient method for ensuring maximum aesthetics in the frontal part of jaws.

Acknowledgements

Geistlich Pharma Ag, the manufacturer of the bone substitute, resorbable membrane and xenogeneic collagen matrix used in this study and Camlog Foundation, supported this trial with an unrestricted grant (CF41106). However, the data remains in the possession of the authors and the sponsor did not in any way interfere with the course of the trial or in the publication of its results.

References

- Akcali, A., Schneider, D., Ünlü, F., Bıçakçı, N., Köse, T., Hämmerle, C.H., 2015. Soft tissue augmentation of ridge defects in the maxillary anterior area using two different methods: a randomized controlled clinical trial. *Clin. Oral Implants Res.* 26, 688–695.
- Batista Jr., E.L., Batista, F.C., Novaes Jr., A.B., 2001. Management of soft tissue ridge deformities with acellular dermal matrix. Clinical approach and outcome after 6 months of treatment. *J. Periodontol.* 72, 265–273.
- Bednarz, W., 2011. The thickness of periodontal soft tissue ultrasonic examination-current possibilities and perspectives. *Dent. Med. Probl.* 48, 303–310.
- Bednarz, W., Zieliniska, A., 2011. Ultrasonic biometer and its usage in an assessment of periodontal soft tissue thickness and comparison of its measurement accuracy with a bone sounding method. *Dent. Med. Probl.* 48, 481–489.
- Berglundh, T., Lindhe, J., 1996. Dimension of the periimplant mucosa. Biological with revisited. *J. Clin. Periodontol.* 23, 971–973.
- De Bruyckere, T., Eghbali, A., Younes, F., De Bruyn, H., Cosyn, J., 2015. Horizontal stability of connective tissue grafts at the buccal aspect of single implants: a 1-year prospective case series. *J. Clin. Periodontol.* 42, 876–882.
- Dominiak, M., Lysiak-Drwal, K., Saczko, J., Kunert-Keil, C., Gedrange, T., 2012a. The clinical efficacy of primary culture of human fibroblasts in gingival augmentation procedures—a preliminary report. *Ann. Anat.* 194, 502–507.
- Dominiak, M., Mierzwa, D., Puzio, M., Gedrange, T., 2012b. Clinical evaluation of the effectiveness of using a collagen matrix (Mucograft prototype) in gingival recession coverage—pilot study. *J. Stomatol.* 65, 184–197.
- Eghbali, A., De Bruyn, H., Cosyn, J., Kerckaert, I., Van Hoof, T., 2016. Ultrasonic assessment of mucosal thickness around implants: validity, reproducibility, and stability of connective tissue grafts at the buccal aspect. *Clin. Implant Dent. Relat. Res.* 18, 51–61.
- Froum, S.J., Khouly, I., Tarnow, D.P., Froum, S., Rosenberg, E., Corby, P., Kye, W., Elian, N., Schoor, R., Cho, S.C., 2015. The use of a xenogeneic collagen matrix at the time of implant placement to increase the volume of buccal soft tissue. *Int. J. Periodontics Restorative Dent.* 35, 179–189.
- Grunder, U., 2011. Crestal ridge width changes when placing implants at the time of tooth extraction with and without soft tissue augmentation after a healing period of 6 months: report of 24 consecutive cases. *Int. J. Periodontics Restorative Dent.* 31, 9–17.
- Hürzeler, M.B., Weng, D., 1999. A single-incision technique to harvest subepithelial connective tissue graft from the palate. *Int. J. Periodontics Restorative Dent.* 19, 279–287.
- Jung, R.E., Sailer, I., Hämmerle, C.H., Attin, T., Schmidlin, P., 2007. In vitro color changes of soft tissue caused by restorative materials. *Int. J. Periodontics Restorative Dent.* 27, 251–257.
- Kan, J.Y., Morimoto, T., Rungcharassaeng, K., Roe, P., Smith, D.H., 2010. Gingival biotype assessment in the aesthetic zone: visual versus direct measurement. *Int. J. Periodontics Restorative Dent.* 30, 237–243.
- Kao, R.T., Pasquini, K., 2002. Thick vs. thin gingival tissue: a key determinant in tissue response to disease and restorative treatment. *J. Calif. Dent. Assoc.* 30, 521–526.
- Kao, R.T., Fagan, M.C., Conte, G.J., 2008. Thick vs. thin gingival biotypes: a key determinant in treatment planning for dental implants. *J. Calif. Dent. Assoc.* 36, 193–198.
- Langer, B., Calagna, L., 1980. The subepithelial connective tissue graft. *J. Prosthet. Dent.* 44, 363–367.
- Linkevicius, T., Apse, P., Grybauskas, S., Puisys, A., 2009. The influence of soft tissue thickness on crestal bone changes around implants: a 1-year prospective controlled clinical trial. *Int. J. Oral Maxillofac. Implants* 24, 712–719.
- Linkevicius, T., Puisys, A., 2015. The influence of mucosal tissue thickening on crestal bone stability around bone-level implants. A prospective controlled clinical trial. *Clin. Oral Implants Res.* 26, 123–129.
- Lorenzo, R., Garcia, V., Orsini, M., Martin, C., Sanz, M., 2012. Clinical efficacy of a xenogeneic collagen matrix in augmenting keratinized mucosa around implants: a randomized controlled prospective clinical trial. *Clin. Oral Implants Res.* 23, 316–324.
- Moharamzadeh, K., Brook, I.M., Van Noort, R., Scutt, A.M., Smith, K.G., Thornhill, M.H., 2008. Development, optimization and characterization of a full-thickness tissue engineered human oral mucosal model for biological assessment of dental biomaterials. *J. Mater. Sci. Mater. Med.* 19, 1793–1801.
- Mohan, R., Singh, A., Gundappa, M., 2011. Three-dimensional imaging in periodontal diagnosis – utilization of cone beam computed tomography. *J. Indian Soc. Periodontol.* 15 (January (1)), 11–17, <http://dx.doi.org/10.4103/0972-124X.82256>.
- Muller, H.P., Schaller, N., Eger, T., 1999. Ultrasonic determination of thickness of masticatory mucosa: a methodologic study. *Oral Surg. Oral Med. Oral Pathol. Oral Radiol. Endod.* 88, 248–253.
- Ouhayoun, J.P., Sawaf, M.H., Goffiaux, J.C., Etienne, D., Forest, N., 1988. Re-epithelialization of a palatal connective tissue graft transplanted in a non-keratinized alveolar mucosa: a histological and biochemical study in humans. *J. Periodontol. Res.* 23, 127–133.
- Rasperini, G., Acunzo, R., Cannalire, P., Farronato, G., 2015. Influence of periodontal biotype on root surface exposure during orthodontic treatment: a preliminary study. *Int. J. Periodontics Restorative Dent.* 35 (September–October (5)), 665–675, <http://dx.doi.org/10.11607/prd.2239>.
- Raetzke, P.B., 1985. Covering localized areas of root exposure employing the envelope technique. *J. Periodontol.* 56, 397–402.
- Schlegel, K.A., Janson, O., Heumann, C.H., Toutenburg, H., 1994. Attached gingiva and periimplantitis. *Z. Zahnarzt. Implantol.* 10, 212–218.
- Schallhorn, R.A., McClain, P.K., Charles, A., Clem, D., Newman, M.G., 2015. Evaluation of a porcine collagen matrix used to augment keratinized tissue and increase soft tissue thickness around existing dental implants. *Int. J. Periodontics Restorative Dent.* 35, 99–103.
- Scharf, D.R., Tarnow, D.P., 1992. Modified roll techniques for localized alveolar ridge augmentation. *Int. J. Periodontics Restorative Dent.* 12, 415–425.
- Schneider, D., Grunder, U., Ender, A., Hämmerle, C.H.F., Jung, R.E., 2011. Volume gain and stability of peri-implant tissue following bone and soft tissue augmentation: 1-year results from a prospective cohort study. *Clin. Oral Implants Res.* 22, 28–37.
- Schulz, K.F., Altman, D.G., Moher, D., CONSORT Group, 2011. CONSORT 2010 statement: updated guidelines for reporting parallel group randomised trials. *Int. J. Surg.* 9 (8), 672–677, <http://dx.doi.org/10.1016/j.ijsu.2011.09.004>, Epub 2011 Oct 13.
- Sculan, A., Gruber, R., Bosshardt, D.D., 2014. Soft tissue healing around teeth and dental implants. *J. Clin. Periodontol.* 41, 6–22.
- Slak, B., Daabous, A., Bednarz, W., Strumban, E., Maev, R.G., 2015. Assessment of gingival thickness using an ultrasonic dental system prototype: a comparison to traditional methods. *Ann. Anat.* 199, 98–103.
- Studer, S., Allen, E., Rees, T., Kouba, A., 1997. The thickness of masticatory mucosa in the human hard palate and tuberosity as potential donor sites for ridge augmentation procedures. *J. Periodontol.* 68, 145–151.
- Studer, S.P., Lehner, C., Bucher, A., Schäfer, P., 2000. Soft tissue correction of a single-tooth pontic space: a comparative quantitative volume assessment. *J. Prosthet. Dent.* 83, 402–411.
- Speroni, S., Cicciu, M., Maridati, P., Grossi, G.B., Maiorana, C., 2010. Clinical investigation of mucosal thickness stability after soft tissue grafting around implants: a 3-year retrospective study. *Indian J. Dent. Res.* 21, 474–479.
- Thoma, D.S., Jung, R.E., Schneider, D., Cochran, D.L., Ender, A., Jones, A.A., Görlach, C., Uebersax, L., Graf-Hausner, U., Hämmerle, C.H.F., 2010. Soft tissue volume augmentation by the use of collagen-based matrices: a volumetric analysis. *J. Clin. Periodontol.* 37, 659–666.
- Thoma, D.S., Benic, G.I., Zwahlen, M., Hämmerle, C.H., Jung, R.E., 2009. A systematic review assessing soft tissue augmentation techniques. *Clin. Oral Implants Res.* 20, 146–165.

- Uchida, H., Koboyashi, K., Nagao, M., 1989. Measurement in vivo of masticatory mucosal thickness with 20 MHz B-mode ultrasonic diagnostic equipment. *J. Dent. Res.* 68, 95–100.
- Windisch, S.I., Jung, R.E., Sailer, I., Studer, S.P., Ender, A., Hämmerle, C.H., 2007. A new optical method to evaluate three-dimensional volume changes of alveolar contours: a methodological in vitro study. *Clin. Oral Implants Res.* 18, 545–551.
- Wiesner, G., Esposito, M., Worthington, H., Schlee, M., 2010. Connective tissue grafts for thickening peri-implant tissues at implant placement. One-year results from an explanatory split-mouth randomised controlled clinical trial. *Eur. J. Oral Implantol.* 3, 27–35.
- Zuhr, O., Hürzeler, M., 2012. *Plastic-Esthetic Periodontal and Implant Surgery*, 1st ed. Quintessence, Berlin.
- Zucchelli, G., Mele, M., Stefanini, M., Mazzotti, C., Marzadori, M., Montebugnoli, L., de Sanctis, M., 2010. Patient morbidity and root coverage outcome after subepithelial connective tissue and de-epithelialized grafts: a comparative randomized-controlled clinical trial. *J. Clin. Periodontol.* 37, 728–738.